

# Microfilariae in Bone Marrow Aspirates: Report of a Case

UMASHANKAR T, PJ YARANAL

## ABSTRACT

Lymphatic filariasis is a common public health problem in the endemic areas. *Wuchereria bancrofti* is the most common parasite which causes lymphatic filariasis in India. The microfilariae are demonstrated in the peripheral blood, body fluids, fine needle aspirates and in bronchial brushings. Microfilariae are an uncommon finding in the bone marrow and their presence may be an incidental finding in the absence of the clinical features of lymphatic filariasis. The

peripheral blood may or may not reveal the microfilariae and eosinophilia is absent in a majority of the cases. All the bone marrow aspirates must be screened for microfilariae in the endemic areas, to identify the asymptomatic carriers.

We are reporting here a case of a 17-year old female who had pancytopenia, a megaloblastic marrow and *W. bancrofti* microfilariae in the bone marrow.

**Key Words:** Microfilariae, Bone marrow, Filariasis

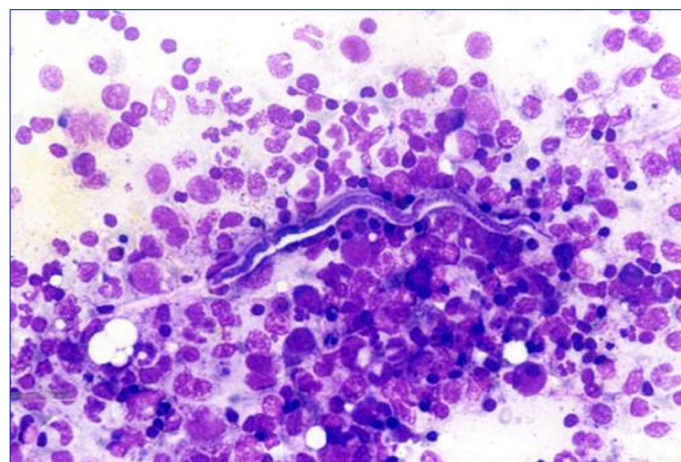
## INTRODUCTION

Lymphatic filariasis is a major public health problem in the endemic areas of India. Apart from the blood and the lymph node aspirates, microfilariae are demonstrated in the fine needle aspirate smears (FNAC) from various sites like the thyroid, breast and subcutaneous nodules, in cervical scrapes and in bronchial washings, as well as in body fluids [1-4]. Microfilariae in the bone marrow aspirates is a rare finding. A few cases have been reported in the literature in association with various haematological findings, such as peripheral blood cytopenia, bone marrow hypoplasia, megaloblastic anaemia and acute lymphoid leukaemia [5-10].

## CASE REPORT

A 17-year old female patient presented with a history of weakness and pallor. There was no other significant clinical history or a history of previous medications. On examination, she was found to be poorly built and afebrile and she had severe pallor. She had a pulse rate of 110 per minute and a blood pressure of 110/70mmHg. There was no organomegaly or significant lymphadenopathy.

Her blood counts revealed a haemoglobin level of 5.7gm per dl and a red blood cell (RBC) count of 1.43 millions per dl and her haematocrit was 16.8%. The mean corpuscular volume was 117.5fl, the mean corpuscular haemoglobin was 39.6pg and the mean corpuscular haemoglobin concentration was 33.4%. The total leucocyte count was 3,200 cells per cmm and the platelet count was 80,000 per cmm. The differential leucocyte count was as follows: neutrophils -25%, lymphocytes- 70%, eosinophils -02% and monocytes -03%. The absolute eosinophil count was 70 cells per cmm and the erythrocyte sedimentation rate was 85mm in the first hour as per the Westergren method. The peripheral blood smears showed pancytopenia with macro-ovalocytic RBCs, hypersegmented neutrophils and low platelet counts. A few sheathed microfilariae were seen in the blood smears. They were morphologically characterized as the microfilariae of *W. bancrofti*, as they lacked terminal nuclei. The patient was advised bone marrow aspiration for the evaluation of anaemia and pancytopenia. After taking her informed written consent, bone marrow was aspirated from her sternum. Bone marrow smears were prepared and they were stained



**[Table/Fig-1]:** Photomicrograph showing a sheathed microfilaria (*W. bancrofti*) in bone marrow aspirate within marrow fragments. (Leishman's stain, X 400)

with Leishman's stain. The smears were hypercellular; the erythroid series was hyperplastic and it showed a megaloblastic maturation. The myeloid series showed giant metamyelocytes and stab forms. Multiple sheathed microfilariae of *W. bancrofti* were seen within the bone marrow fragments [Table/Fig-1]. A diagnosis of megaloblastic anaemia with *W. bancrofti* microfilaraemia was made.

She was started on vitamin B12, folic acid and anti-filarial treatment. Further evaluations were not possible as the patient was lost to follow-up.

## DISCUSSION

Filariasis is a major health problem in endemic areas. In humans, *W. bancrofti* is the most common filarial parasite which causes lymphatic filariasis. In the natural history of lymphatic filariasis, the adult worm lodges in the lymphatics and the microfilariae circulate in the blood stream. Lymphatic filariasis commonly presents as lymphangitis, elephantiasis and peripheral blood eosinophilia. During their circulation in the peripheral blood, the microfilariae may get lodged in various organs and body fluids and be picked up in the cytological samples. They are found in the FNAC smears from the thyroid [1,2,3], breast [1,2,3], lymph nodes [1,3] and subcutaneous nod-

ules [1,3], in cervical scrape smears [1], in bronchial washings [1,4] and in body fluids [1]. It is also possible that they may get trapped in the bone marrow during their circulation in the peripheral blood.

Including the present case, none of the published cases where microfilaria was found in the bone marrow aspirates, had a classical clinical presentation of lymphatic filariasis [5-11]. A diagnosis of filariasis was made after demonstrating the microfilariae in the bone marrow aspirate or in the peripheral blood smears. In a few reported cases, microfilariae were present in the bone marrow aspirates but not in the peripheral blood, [5,9,10]. Panja et al., [11] described a case of atypical filariasis who had meningo-encephalitis, proptosis, fever, anaemia and joint pain without any clinical features of lymphatic filariasis. The bone marrow aspirates had shown microfilariae. The microfilaria of *W. bancrofti* is the most common type of parasite that is demonstrated in the bone marrow [6,7,9,11]. One case of *Mansonella perstans* microfilaria was described in the bone marrow of a HIV positive patient who also had neutropenia and a hypoplastic marrow [8]. It has not been clearly understood how these microfilariae reach the bone marrow. In monkeys, it was demonstrated that a fraction of the microfilariae was present in the circulation and a major portion was sequestered in the microcirculation. It is possible that these microfilariae from the microcirculation migrated and entered the bone marrow by crossing the vessel wall, which was attributed to their boring ability [7].

Peripheral blood eosinophilia is a common haematological finding in filariasis. But in a majority of the reported cases, in which microfilariae were demonstrated in the bone marrow, eosinophilia was absent [5,7,9]. A similar finding was noted in our case also. The absence of peripheral blood eosinophilia in these cases may be attributed to the oxidative stress which was associated with the chronic and occult filariasis, which had caused altered immune responses [12]. Anaemia and pancytopenia were the other frequent peripheral blood findings [5,6,7,9].

The bone marrow may be aplastic, hypoplastic or hyperplastic with a normoblastic or a megaloblastic maturation [5,7,9,11]. The bone marrow hypoplasia may be attributed to drugs [5] and viral infections such as those which are caused by varicella [6] and HIV [8] or it may be idiopathic [5]. Sharma et al., [5] described six cases of microfilariae in the bone marrow aspirates, among which five had bone marrow hypoplasia or aplastic. In two cases with aplastic anaemia, the aetiology was not known and it was considered as idiopathic. Shenoj et al., [9] described three cases of microfilariae in the bone marrow aspirates, among which one had aplastic anaemia and the other had megakaryocytic aplasia. They opined that the blood and the bone marrow changes were unrelated to the filarial infestation. Arundhati et al., [10] described a case of acute lymphoblastic leukaemia in association with *W.*

*bancrofti* microfilariae in the bone marrow aspirates and it was likely that the immunocompromised status in the leukaemia had made the patient more susceptible for the parasitic infestation. In our case, the pancytopenia, macrocytic RBCs and the hypersegmentation of the neutrophils were attributed to the megaloblastic anaemia which was caused by a nutritional deficiency. We consider that the presence of microfilariae in the bone marrow is an incidental finding and that filariasis has no role in the causation of megaloblastic anaemia. However, in the present case, the altered immune status which was associated with the anaemia may be the cause of the asymptomatic microfilariae carrier status and the absence of the eosinophilia. To conclude, microfilariae in the bone marrow aspirates may be an incidental finding in the absence of the clinical features of filariasis. In the endemic areas, all the bone marrow aspirates must be screened for microfilariae, to detect any asymptomatic carriers. Further documentation and investigations are needed to understand the possible aetiological role of filariasis in various haematological manifestations such as pancytopenia and bone marrow hypoplasia.

## REFERENCES

- [1] Yenkeswar PN, Kumbhalkar DT, Bobhate SK. Microfilariae in fine needle aspirates: a report of 22 cases. *Indian J Pathol Microbiol* 2006;49:365-69.
- [2] Kishore B, Khare P, Gupta RJ, Bisht SP. The microfilariae of *Wuchereria bancrofti* in cytologic smears: a report of 5 cases with unusual presentations. *Acta Cytol* 2008;52:710-12.
- [3] Gupta S, Gupta R, Bansal B, Singh S, Gupta K, Kudesia M. The significance of the incidental detection of filariasis on aspiration smears: a case series. *Diagn Cytopathol* 2010;38:517-20.
- [4] Anupindi L, Sahoo R, Rao RV, Verghese G, Rao PV. Microfilariae in the bronchial brushing cytology of symptomatic pulmonary lesions. A report of two cases. *Acta Cytol* 1993;37:397-99.
- [5] Sharma S, Rawat A, Chowhan A. Microfilariae in bone marrow aspiration smears; their correlation with marrow hypoplasia: a report of six cases. *Indian J Pathol Microbiol* 2006;49:566-68.
- [6] Hemachandran M, Varma N, Varma S. Aplastic anaemia following a varicella infection with a coexistent microfilaraemia of *Wuchereria bancrofti*- a case report. *Indian J Pathol Microbiol* 2003;46:662-63.
- [7] Pradhan S, Lahiri VL, Elhence BR, Singh KN. The microfilariae of *Wuchereria bancrofti* in bone marrow smears. *Am J Trop Med Hyg* 1976;25:199-200.
- [8] Molina MA, Cabezas MT, Giménez MJ. *Mansonella perstans* filariasis in an HIV patient: a finding in the bone marrow. *Haematologica* 1999;84:861.
- [9] Shenoj U, Pai RR, Pai U, Nandi GK, Adhikari P. Microfilariae in bone marrow aspiration smears. *Acta Cytol* 1998;42:815-16.
- [10] Arundhati, Kumar A, Kumar R. Acute lymphoblastic leukaemia with microfilaria: a rare coincidence in bone marrow aspirates. *Indian J Hematol Blood Transfus* 2011; 27:111-12.
- [11] Panja M, Ganguly S, Kar AK, Chhetri MK. Atypical filariasis. *J Assoc Physicians India* 1987;35:596-97.
- [12] Pal BK, Kulkarni S, Bhandari Y, Ganesh BB, Goswami K, Reddy MV. Lymphatic filariasis: a possible pathophysiological nexus with oxidative stress. *Trans R Soc Trop Med Hyg* 2006;100:650-55.

### AUTHOR(S):

1. Dr. Umashankar T
2. Dr. PJ Yaranal

### PARTICULARS OF CONTRIBUTORS:

1. Associate Professor, Department of Pathology, Yenepoya Medical College, Mangalore, India.
2. Associate Professor, Department of Pathology, Yenepoya Medical College, Mangalore, India.

### NAME, ADDRESS, E-MAIL ID OF THE CORRESPONDING AUTHOR:

Dr. Umashankar T  
Associate Professor, Department of Pathology,  
Yenepoya Medical College, Mangalore - 575018, India.  
Phone: 9880568839  
E-mail: tumashankar@hotmail.com

### FINANCIAL OR OTHER COMPETING INTERESTS:

None.

Date of Submission: **Jun 11, 2012**  
Date of Peer Review: **Jul 30, 2012**  
Date of Acceptance: **Aug 22, 2012**  
Date of Publishing: **Sep 30, 2012**